

CATH & HEMODYNAMICS OF CONSTRICTIVE & RESTRICTIVE CARDIOMYOPATHY

Constrictive pericarditis: (C.P):

- A result of scar and consequent loss of normal elasticity of pericardial sac

↓

Defective ventricular filling in mid to late diastole

↓

∴ Majority of ventricular filling occurs in early diastole and it is rapid and ventricular volume does not increase after end of early filling period

Restrictive cardiomyopathy: (RCM):

- NON-DILATED rigid ventricle,

↓

Resulting in severe diastolic dysfunction and restrictive filling that produces hemodynamic changes similar to constrictive pericarditis

- CP: Pericardial disease
- RCM: Myocardial Disease

Constriction vs Restriction

00:02:18

- Dx has important therapeutic implications
- Clinical presentation similar: RHF
- A thick pericardium is not necessarily constrictive
- A restrictive process may constrict

- Echo and hemodynamic features may overlap

CP: (Constrictive pericarditis)

00:03:08

- Scarring of both parietal + visceral layers overlying cardiac chambers.
- Causes:
 - i. Tuberculosis (m/c in INDIA)
 - ii. Idiopathic/ Viral pericarditis (m/c in west)
 - iii. Mediastinal irradiation
 - iv. Open heart surgery
 - v. CRF (chronic Renal failure)
 - vi. Connective tissue disorder
 - vii. MALIGNANCY

PATHOPHYSIOLOGY: = Marked restriction of filling

= Ventricular interdependence

→ On inspiration, due to

Decreased intrathoracic pressure, increase venous return to right side of heart

↓

Increase blood across RA ,RV

⇓

- Now it due to diseased pericardium, ventricular filling is done in early phase of diastole, while the mid to late phase of diastole filling is not present and due to elastic nature of pericardium, the

volume of blood in RV pushes the interventricular septum to left side decreasing LV. Volume



Here any changes to RV Inflow/ outflow will not be transmitted to the pericardium, but will be transmitted to intracardiac chambers (i.e., LV)

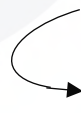∴ = Failure of transmission of intrathoracic pressure to intracardiac chambers

Features of restriction to cardiac filling:

- Gradual development of systemic and pulmonary venous hypertension



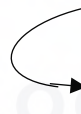Atrial pressure = 10-18mm Hg



Systemic venous congestion



Atrial pressure = 18-30 mm of Hg



Effort dyspnea, orthopnea



[PULMONARY VEINS = OUTSIDE PERICARDIUM]

= fall in stroke volume:

- Increase HR < increase systemic vascular resistance
- Inability to augment cardiac output during exercise
→ fatigue
- Cardiac cachexia

(Resting cardiac output falls)

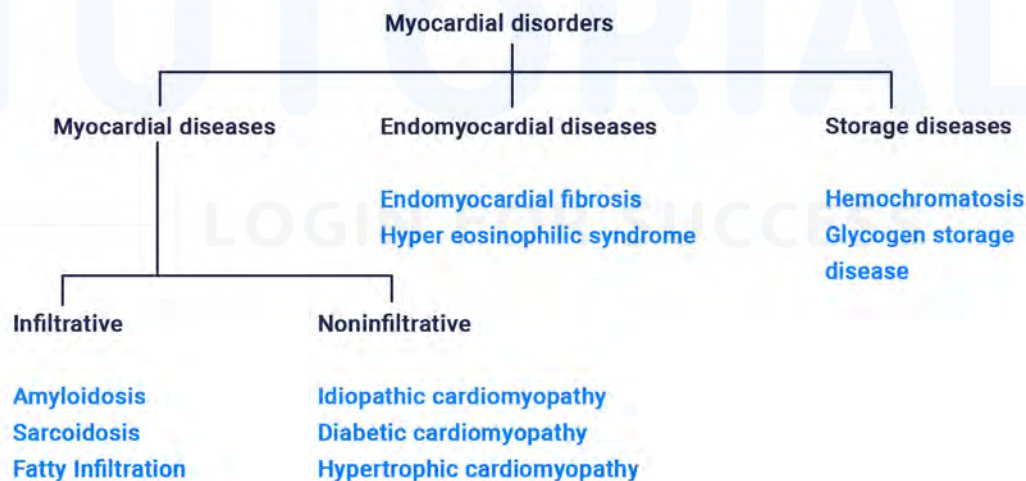
Normally:

- Inspiratory decrease in intrathoracic pressure is transmitted to all cardiac chambers
- Decrease in pressure in pulmonary veins and LV.
- Decrease PCWP associated with corresponding decrement in LV. Pressure
- Gradient that drives LV filling maintained

However:

- In CP → there is loss of transmission of intrathoracic pressure

RESTRICTIVE CARDIOMYOPATHY: 00:06:14



Normal pericardium:

<p>Visceral layer</p> <p>↓</p> <p>= Monolayer of mesothelial cells, collagen and elastin fibers</p> <p>= Associated with origins of great</p>	<p>Parietal layer</p> <p>↓</p> <p>Made up of collagen and elastin fibers</p>
---	--

PATHOPHYSIOLOGY OF CCP:

- Chronic constrictive pericarditis (CCP) is end stage of an inflammatory process involving pericardium
- Etiology
 - Developed country = idiopathic, post sx, Radiation
 - Developing country = Tuberculosis
- Initial insult → Takes years to develop into CCP

↓

End result = Dense fibrosis often calcification and adhesion of parietal and vascular pericardium

↓ Resulting in

- Marked restriction of filling
- Ventricular interdependence
- Failure of transmission of intrathoracic pressure to intracardiac chambers

Resulting in equilibrium of filling pressure in all chambers

i.e., End diastolic pressure in all 4 chambers would be equal

- During early diastole, ventricles fill abnormally. Rapidly due to marked elevation of atrial pressures and almost all ventricular filling occurs in early diastole
 - Ventricular interdependence: Filling of one ventricle limits the simultaneous filling of other ventricle owing to shared mechanism constraint
 - LV & RV diastole pressure typically track closely and rarely differ by more than 3-5 mm Hg
- ↓
- But in Restrictive cardiomyopathy, where diastole pressure in LV is higher than RV by at least 3-5 mm Hg

∴ Constrictive = RV & LV. Pressure (N)

Restrictive = LV > RV diastole pressure

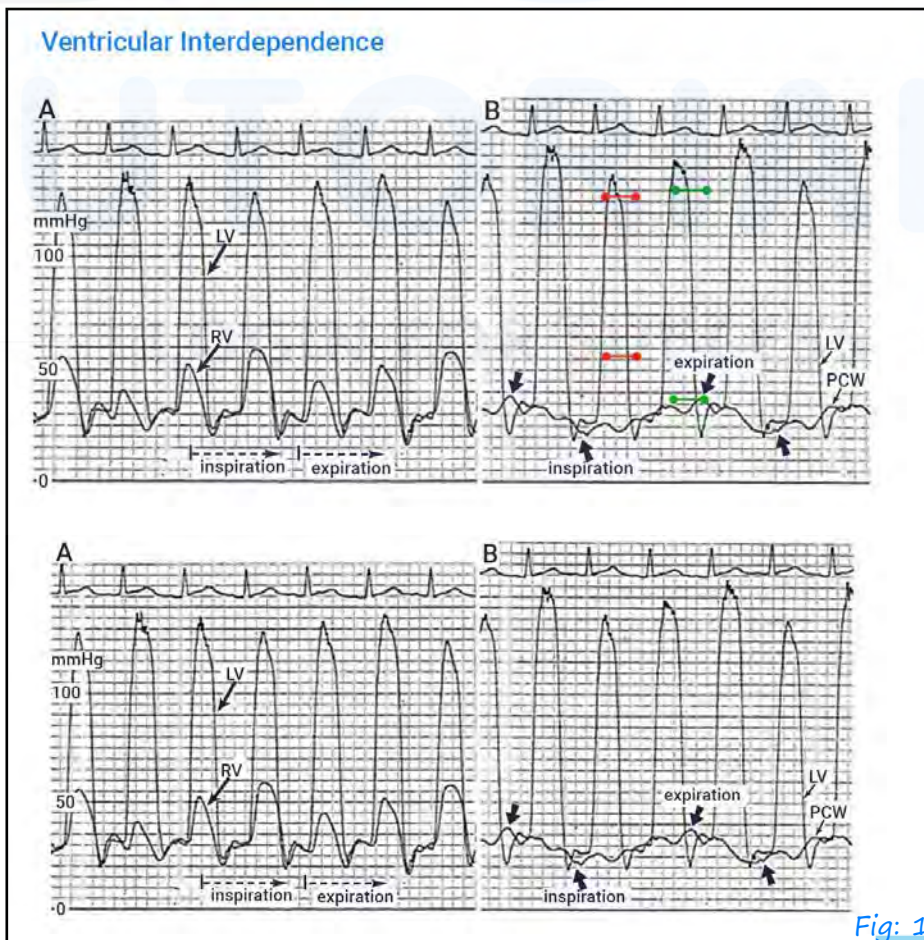


Fig: 1

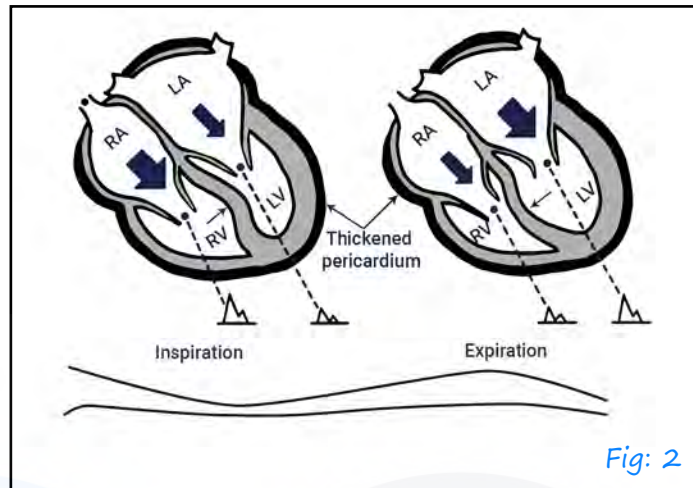


Fig: 2

Loss of transmission of intrathoracic pressures

- Normal

- Inspiratory decrease in ITP transmitted to all cardiac chambers
- Decrease in pressure in pulmonary veins and LV
- Decrease in PCWP accompanied by corresponding decrement in LV pressures
- Gradient that drives LV filling maintained

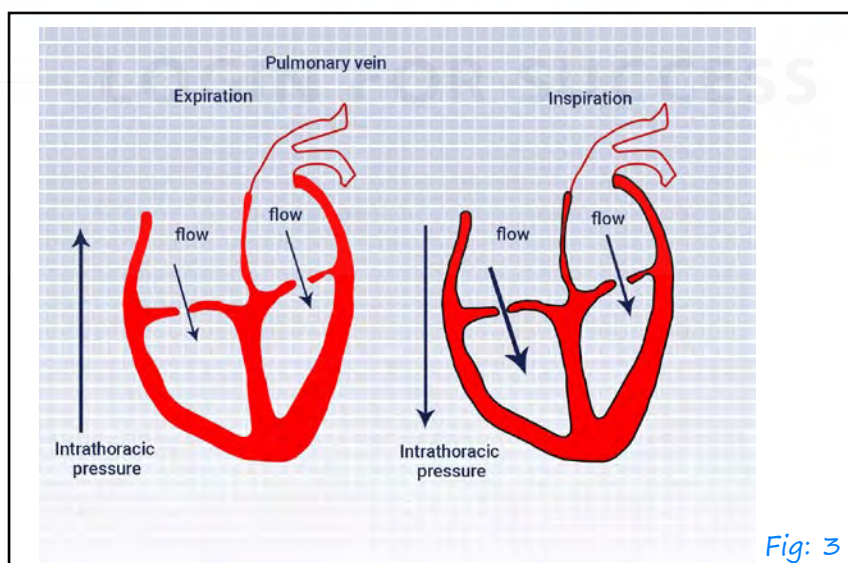
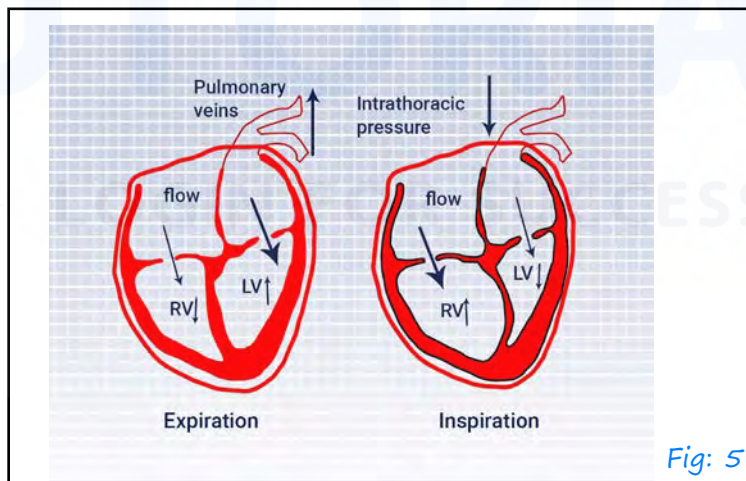
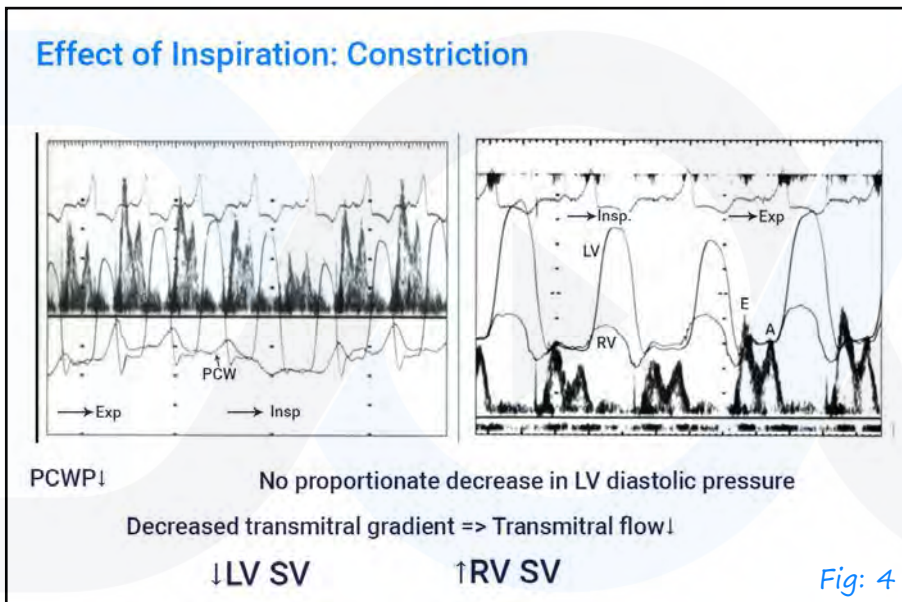


Fig: 3

- Left Atria} Extra pericardial intrathoracic structure



∴ In constrictive pericarditis, LA is not involved, thus it can accommodate blood and orthopnea and back pressure changes/ class IV dyspnea occurs later/ do not occur



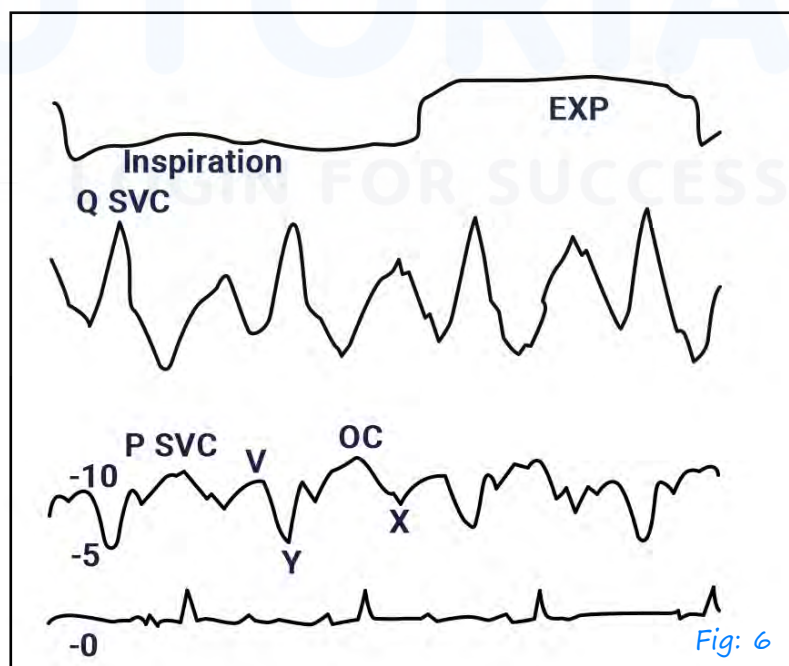
- Restricted filling – elevation of mean pressure
- Early diastole – rapid filling – prominent y descent

- Elevated right atrial pressure
Suction effect due to decrease

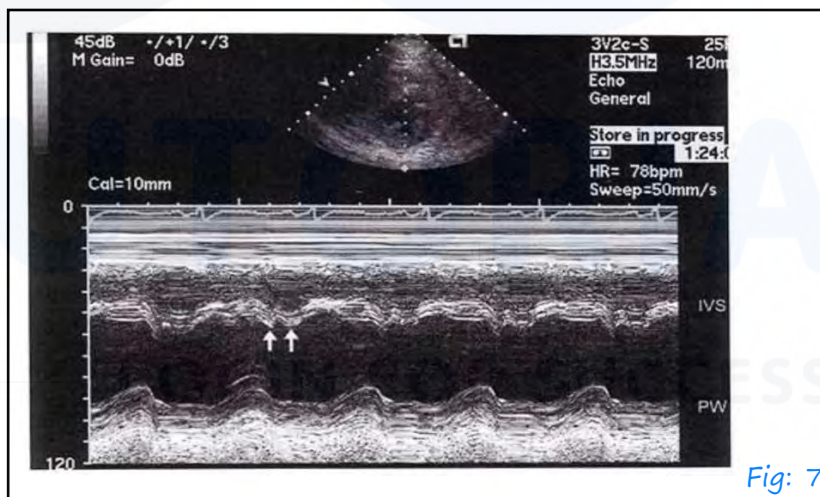


Friedreich's Sign

- Kussmaul's Sign: Inspiratory increase in venous return but failure to decrease intrathoracic pressure to RV.
∴ Failure of column of blood to fall during inspiration
- Abrupt cessation of ventricular filling – “nadir of y descent”
- Physical Examⁿ:



- i. JVP: Rapid γ descent = "freidreich's sign"
 - ↳ Constrictive pericarditis
 - Prominent 'x' descent = Cardiac tamponade
- ii. Kussmaul's sign (also in RHF/ systemic venous congestion / severe TR)
- iii. "Pulsus paradoxus" in 1/3 d cases of constrictive pericarditis, especially effusive constrictive pericarditis
- iv. "Pericardial knock" again a/ with sudden cessation of filling is early diastole
- v. ECG= low voltage QRS complexes, occasionally AF
- vi. CXR: "pencilling" heart border in lateral view due to loss of fat and calcification of pericardium
- vii. M- MODE on ECHO: paradoxical septal wall motion



Septum = abnormal rapid movement – notching in early diastole

Post LV. wall = abrupt posterior motion in early diastole and flat in remaining diastole

- IVC and hepatic vein dilation
- 2D ECHO= increase echogenicity of pericardium from thickening may see effusion
 - Septal bounce may be seen
- ECHO DOPPLER: During Diastole of ventricle on viewing doppler two waves are seen

↓

E= early diastole filling of ventricle

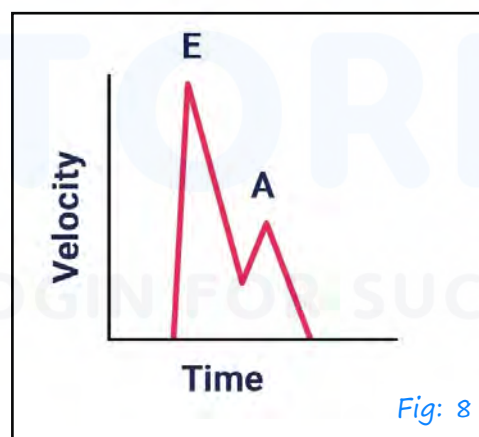
A= atrial contraction

- Normally E/A ratio is less than 2

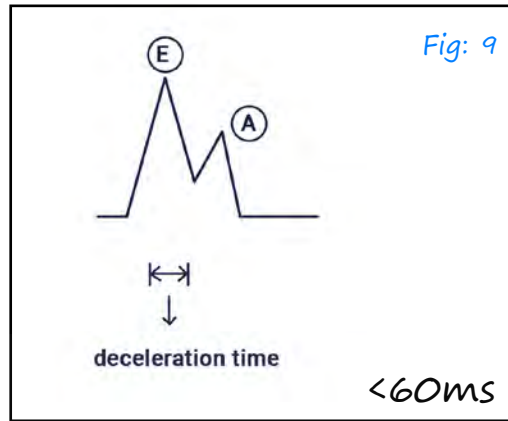
↓

However, here, it is >2 [E/A ratio >2] and deceleration time [: time from peak of E to end of E] is <160 ms.

- Because ventricles fill very rapidly in early diastole



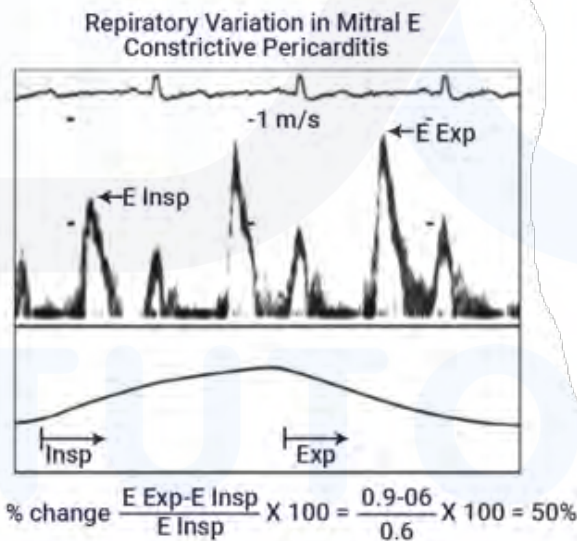
- IVRT = Isovolumetric relaxation time on respiratory cycle
(: end of A and coming of systole of next cycle)



- Respiratory variant on mitral Inflow velocity (most imp)

in constrictive pericarditis

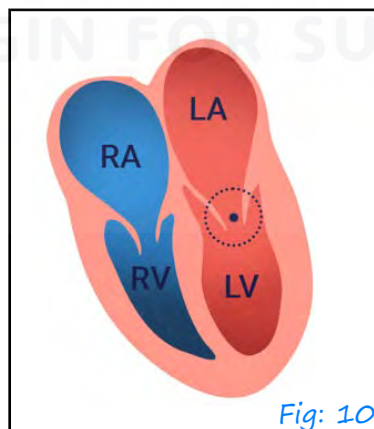
in Restrictive cardiomyopathy



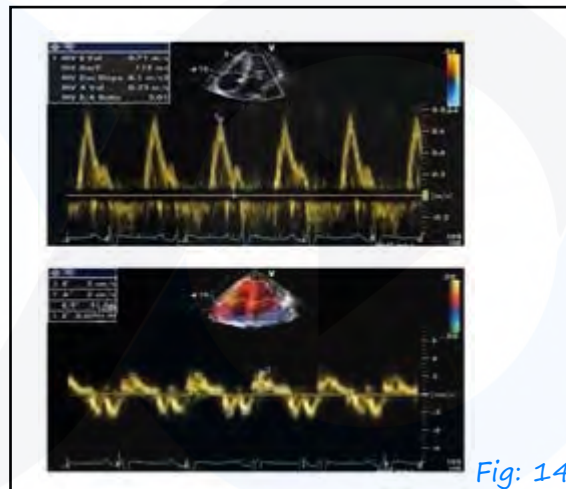
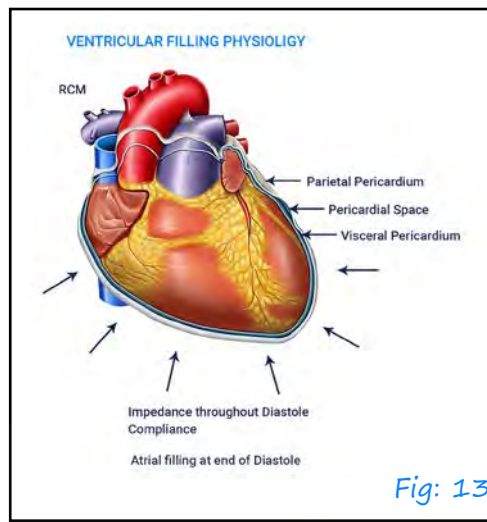
↓

Velocity varies by $< 10\%$

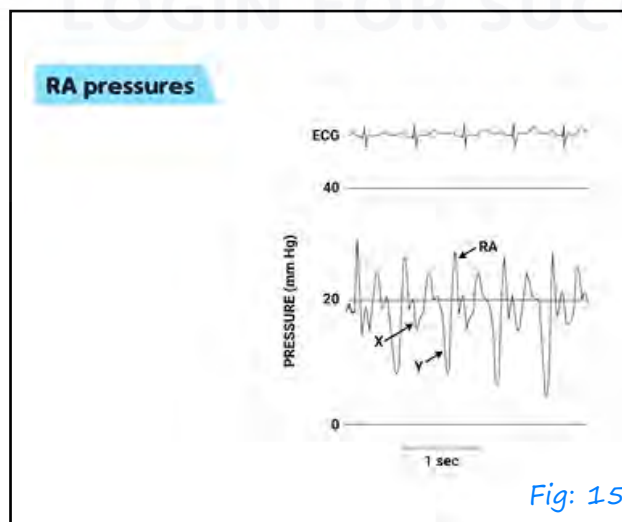
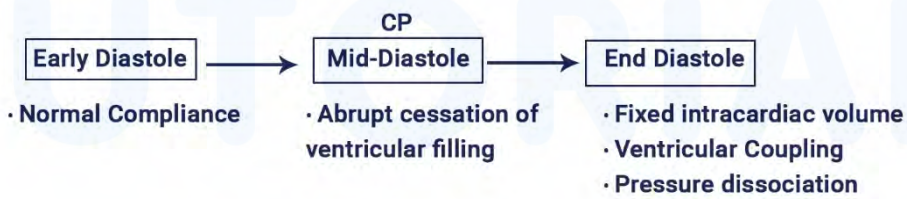
E/A rising by more than 25% on inspiration in TV, on expiration in mv.

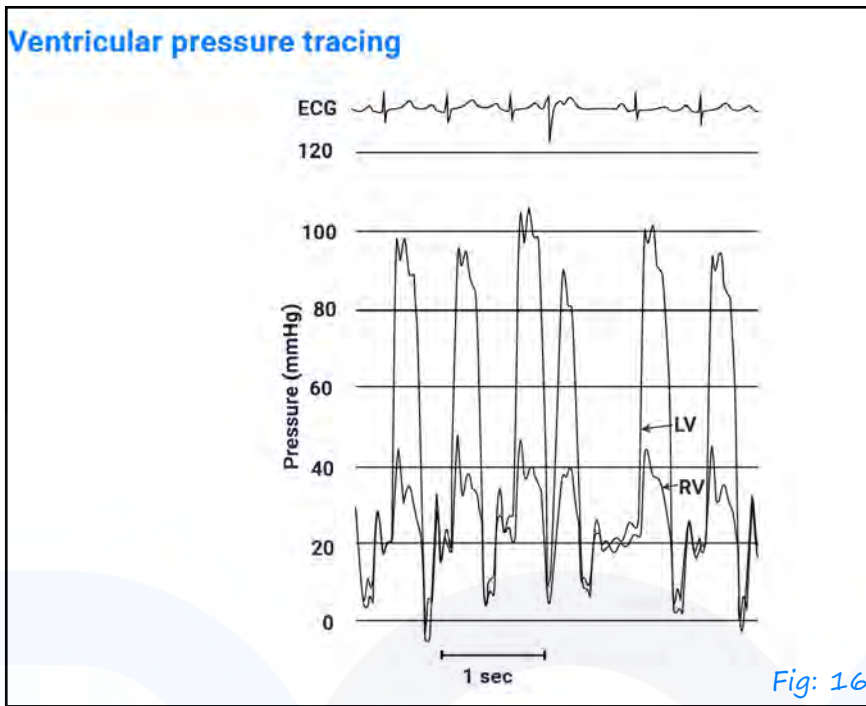


- Tissue doppler of mitral annulus.



VENTRICULAR FILLING PHYSIOLOGY





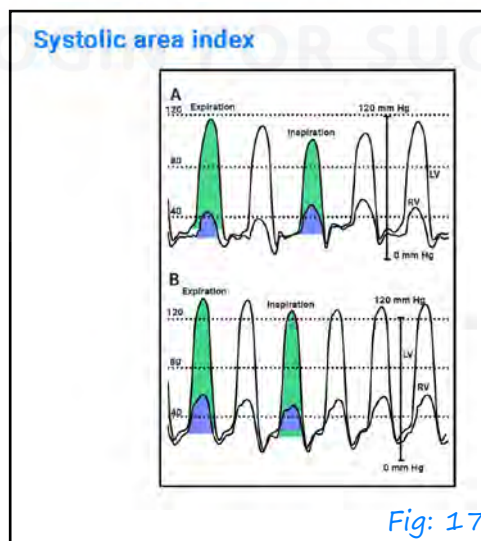
- VIII). IN CCP= discordance between RVSP LVSP during phases of respiration and since pulmonary veins/ LA are extra pericardial

↙ ↘

Pulmonary Artery hypertension does not develop

It PAH develops it is a feature of restrictive cardiomyopathy

∴ RVEDP > 1/3rd of RVSP



- ix) Systolic Area Index: measure RV and LV pressures during inspiration and expiration and

$$\left. \begin{array}{l} \text{RV/LV area in inspiration} \\ \text{RV/LV area in expiration} \end{array} \right\} > 1.1 = \text{CCP}$$

- x) "LV-RV interdependence measurements" has the highest sensitivity and specificity along with increase MPV and increase PPV to make a diagnosis of "CP

RESTRICTIVE CARDIOMYOPATHY:

- PATHOPHYSIOLOGY: impaired ventricular compliance with impedance to filling in a progressive pandiastolic pattern.

In early disease: systolic function may be normal



However, as disease progresses

→ Deterioration in systolic function occurs

- Ventricular diastolic pressures are elevated



"Dip & PLATEAU PATTERN"

OR

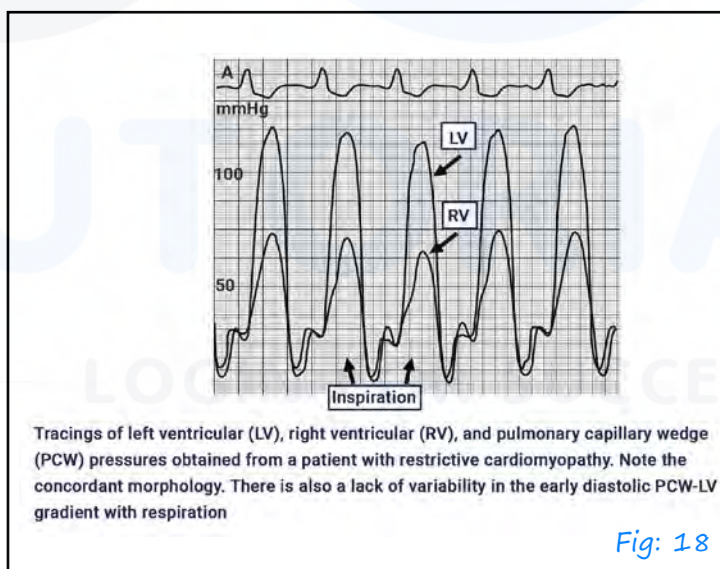
"SQUARE ROOT PATTERN"

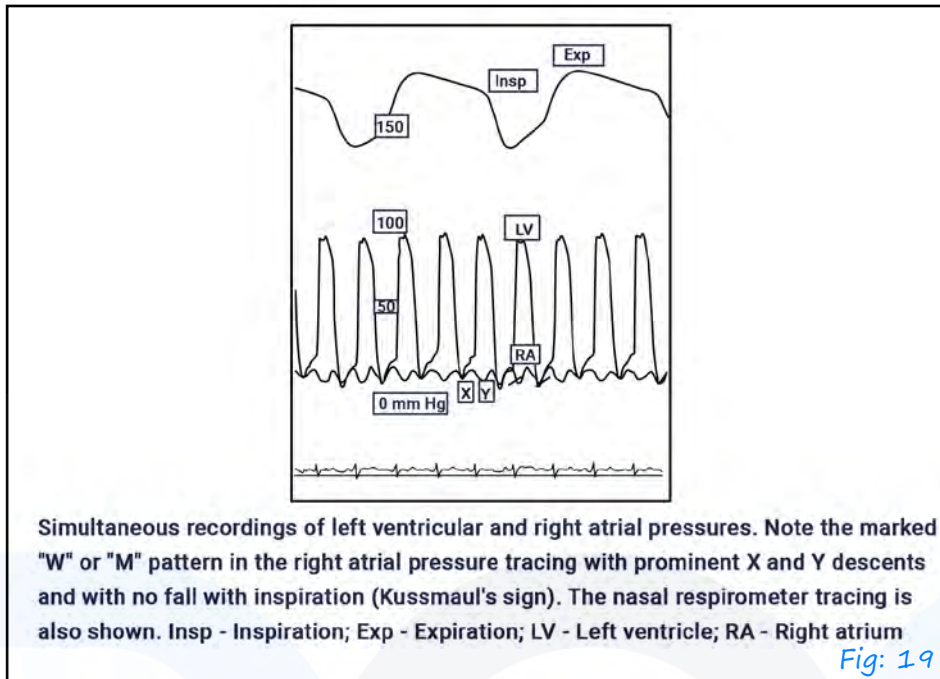
- Presence of Bia trial enlargement is present

- In RCM, inspiratory changes in intrathoracic pressure are transmitted through pericardium to cardiac chambers.
- Lesser ventricular interdependence
- Concordant pattern on ventricular systolic pressure Graph.
- In severe disease, there is no respiratory variations as the right sided chambers become less distensible

JVP:

- Square root pattern / M/W waveform is present
Where x-descent is rapid 'a' and 'v' waves are prominent
- S3 may be heard





Restrictive cardiomyopathy

- *Intrinsic abnormality of diastolic function*
- *Normal LVEDV but \uparrow diastolic pressure*
- *RV + LV diastolic dip and plateau*
- *Equalization of diastolic filling pressures*
- *"Y" descent blunted relative to "X"*
- *Blunted respiratory variation in trans – vascular flows*
- *Kussmaul's sign may be present*
- *Pulsus paradoxus in some*
- *Ventricular concordance*

Problem with filling

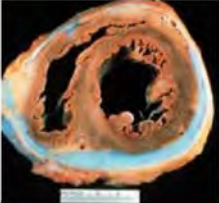

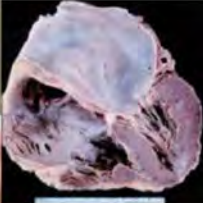
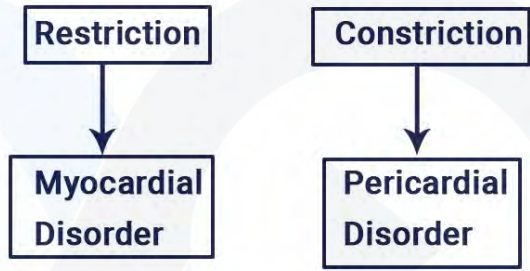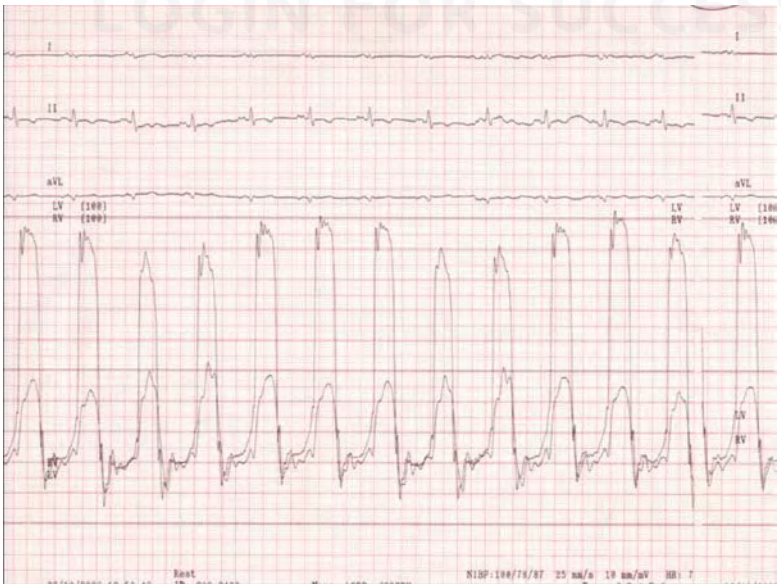
		
Heart failure Elevated Knock Normal Nonspecific	Symptoms JVP gallop LVEF ECG	Heart failure Elevated S3 Normal Nonspecific

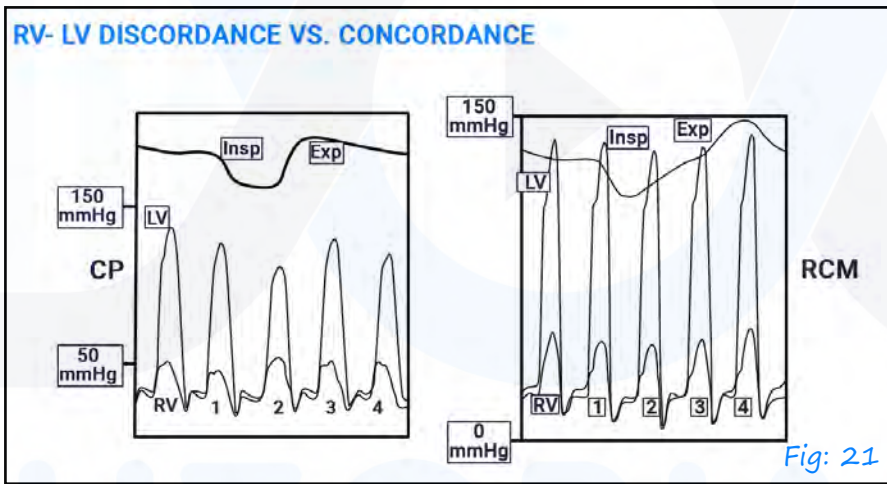
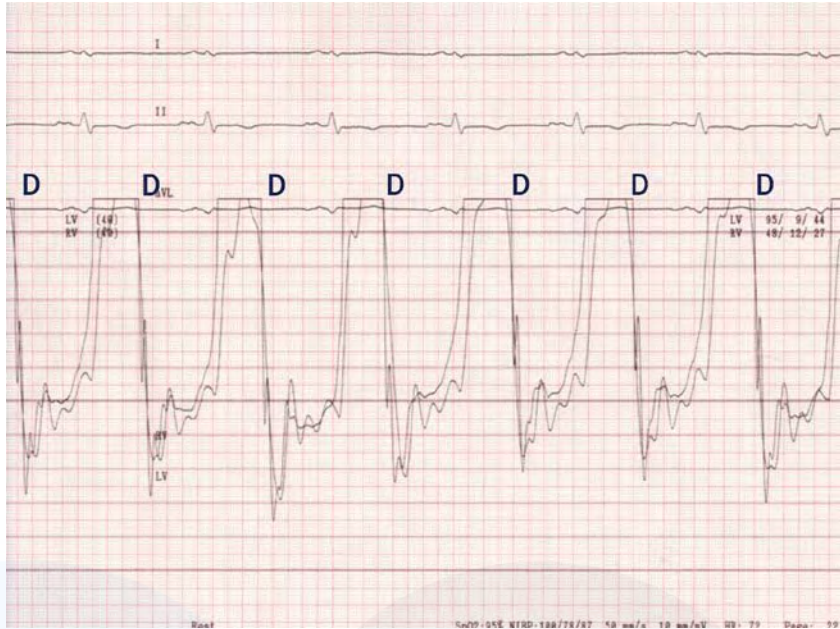
Fig: 20



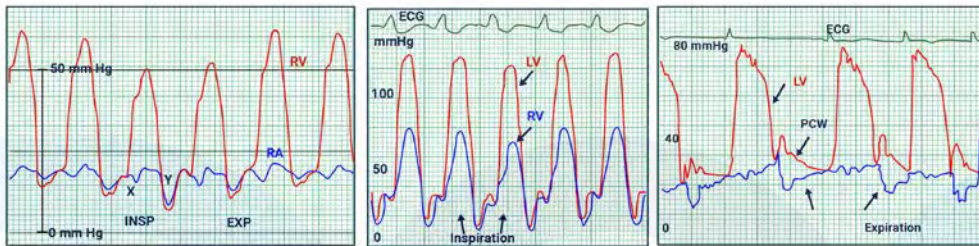
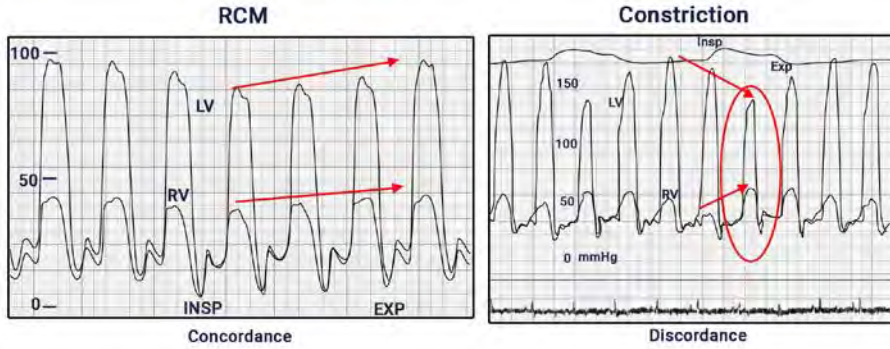
Pathophysiologic Differences

Constriction	Restriction
Myocardial compliance is normal	Abnormal Myocardial compliance
No impedance to Diastolic early filling	Impedance to filling increases throughout the diastole
Total cardiac volume is fixed by the pericardium	Pericardium is compliant
Atria are able to empty into the Ventricles, though at higher Press	Septum is non-compliant
	Reduction of the proportion of LV filling with atrial contraction: => Atrial enlargement
↓	↓
Marked Respiratory effect of LV on the RV	Minimal Respiratory effect of RV on the LV

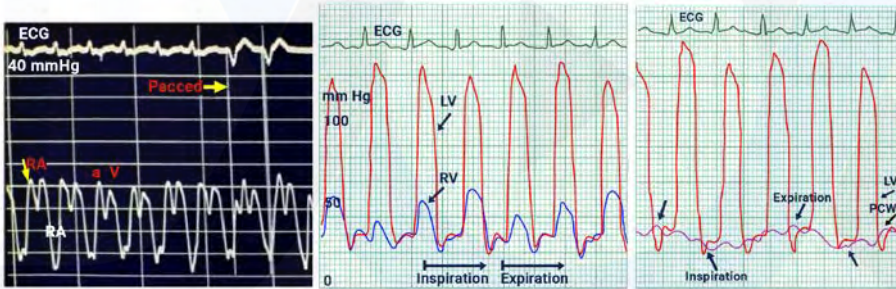




	Sensitivity	Specificity	PPV	NPV
EDP equalisation	60	38	4	57
PAP	93	24	47	25
High RVEDP	93	38	52	89
Dip Plateau	93	57	61	92
Kussmaul's	93	48	58	92
PCW-LV resp Gdt	93	81	78	94
LV/RV ID	100	95	94	100



RV-LV interdependence absent



	Constriction	Restriction
Prominent Y descent in venous pressure	Present	Variable
Paradoxical pulse	-1/3 cases	Absent
Pericardial knock	Present	Absent
Equal right-left side filling pressures	Present	Left at least 3-5 mm Hg > right
Filling pressures >25 mm Hg	Rare	Common
Pulmonary artery	No	Common
Systolic pressure >60 mm Hg		

Parameter	CP	RCM
Septal shudder or bounce	Yes	No
MV Inflow respiratory variation	≥25%	None
TV Inflow respiratory variation	>40%	None
MVDT	Short	<160ms
Hepatic vein reversal	↑DR with exp	
IVRT	↓Exp, ↑Insp	No Δ
TR duration	Increase	No Δ
E/e	<8-10	>15